



The Cranial Nerve Vascular Compression Syndromes

By Michael H. Brisman, M.D., F.A.C.S.

Trigeminal Neuralgia (TN), Hemifacial Spasm (HFS), and Glossopharyngeal Neuralgia (GPN), are cranial nerve hyperactivity syndromes that are usually caused by compression of the cranial nerve (5 - Trigeminal, 7 - Facial, or 9 - Glossopharyngeal) near the nerve root by a small blood vessel. The three syndromes have many similarities in presentation and treatment.

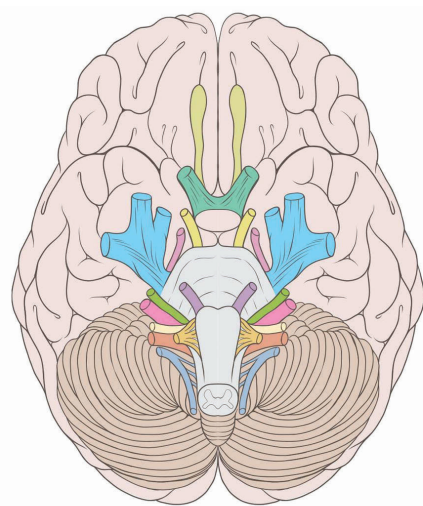














Illustration: Patrick J. Lynch

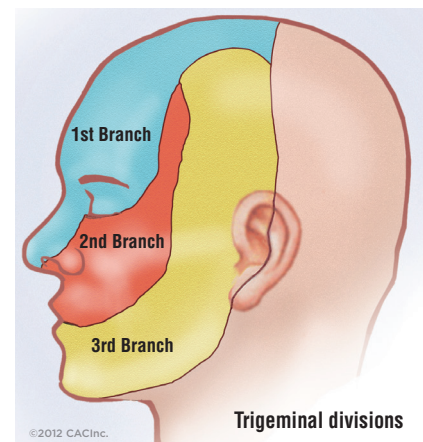
The 12 Cranial Nerves

-  CN I - Olfactory Nerve
-  CN II - Optic Nerve
-  CN III - Oculomotor Nerve
-  CN IV - Trochlear Nerve
-  CN V - Trigeminal Nerve
-  CN VI - Abducens Nerve
-  CN VII - Facial Nerve
-  CN VIII - Vestibulocochlear Nerve
-  CN IX - Glossopharyngeal Nerve
-  CN X - Vagus Nerve
-  CN XI - Spinal Accessory Nerve
-  CN XII - Hypoglossal Nerve

Trigeminal Neuralgia (TN)

General Considerations and Presenting Symptoms

The annual incidence of TN is about 1 in 20,000 people. The average age of presentation is in the 60's. There is a modest female preponderance. TN occurs somewhat more frequently on the right side of the face than the left. People with TN experience severe facial pain in the distribution of the trigeminal nerve. The pain can involve any region of the trigeminal nerve, from the top of the head to the jaw area. TN pain usually involves just one side of the face. A few patients with TN will have symptoms on both sides of the face, but rarely at the same time. While TN can involve any of the trigeminal divisions (V1, V2, or V3), alone or in combination, it usually involves the lower divisions and the lower part of the face. In 20% of TN cases, the first division will be involved, and in 2% of TN cases, the first division is the only division involved. The pain of TN can radiate back to the ear. TN was originally called "tic doloreux", because people sometimes wince when they would get the severe pain, but TN is now recognized as a disorder purely of the sensory pathways and the trigeminal nerve, not as a true "tic" or movement disorder.



©2012 CACInc.

Trigeminal divisions

TN occurs spontaneously. If there has been a shingles rash on the face in the past, this suggests a post-herpetic neuralgia (PHN) of the trigeminal distribution. PHN usually occurs in older people, tends to occur in the V1 distribution, and is difficult to treat. If there has been an injury to the face, this raises the possibility of nerve injury related pain. Nerve injury pain, however, is more likely to be constant, achy, burning, and associated with numbness and dysesthesias. “Classic” TN pain is intermittent, sharp, severe, electric shock pain. It is one of the most severe types of pain. The sharp pains are usually described as “electric shock” like, sometimes as “stabbing”, and rarely as just “intense” pains. TN usually is sporadic, though rarely there will be other family members with TN. TN pain occurs suddenly, is usually brief, and often triggered by mild stimulations in the distribution of the trigeminal nerve, like light touch, chewing, talking, brushing teeth, or a light wind. TN is characterized by spontaneous remission. The pains can go away for months or years, and can then recur. The diagnosis of TN is made by the patient’s symptoms. There are no physical “signs” of trigeminal neuralgia, that is, the physical examination is usually normal. Patients with TN will often seek help from a dentist and will not uncommonly have numerous dental procedures and extractions to try to alleviate their pain. Because visits to the dentist are common, many TN patients will incorrectly attribute their pain to their prior dental procedures. TN is remarkably sensitive to the similar anticonvulsants Tegretol (carbamazepine) and Trileptal (oxcarbazepine). If these medicines are given and tolerated and yet produce no benefit at all, the diagnosis of TN comes into question.

The features of classic TN pain can be summarized with the following 10 “S” terms:

- Spontaneous
- Sporadic (no family history)
- Sharp
- Severe
- Sudden
- Short-lived
- Set off (triggered)
- Sign free (normal exam)
- Sensitive to anticonvulsants
- Spontaneous remissions

Further Classification of TN

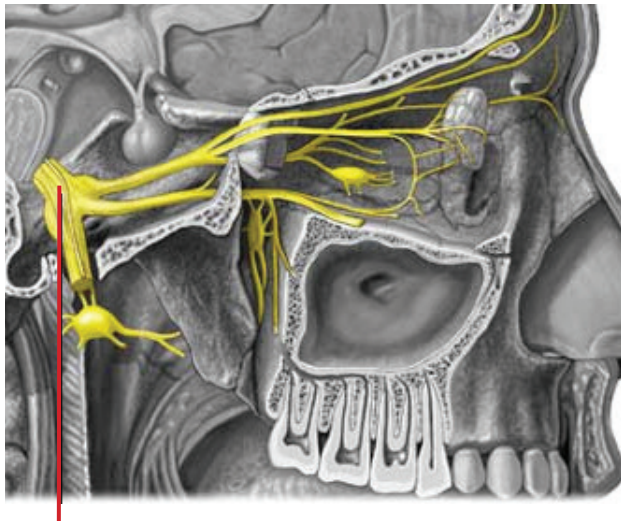
TN patients will sometimes have some non-classic or “atypical” features. It is then referred to “**atypical trigeminal neuralgia.**” These features can include some dull, or achy, or burning components to the pain. There may be some baseline of constant pain. (This should be contrasted with patients who say their pain is “constant,” but on close questioning, will clarify that the pain is not really there all the time, but rather, “comes and goes”, just very frequently.) There may be reported some abnormal feelings, or “dysesthesias”, or even numbness at times. Sometimes the pains are not clearly triggered but just come on by themselves.

Sometimes there is no clear response from tegretol. Also, if a person has been treated with medicines or has had a denervating (“nerve blocking”) procedure, their symptoms may differ somewhat from the “classic” symptoms. Nonetheless, if the patient has as a major feature the sharp, severe, sudden, brief pains in the trigeminal distribution, the problem is still felt to be trigeminal neuralgia, and should be treated according to the standard trigeminal neuralgia algorithm.

There are patients with chronic facial pain that do not seem to have trigeminal neuralgia or any other clearly defined pain syndrome. These patients will often have constant, moderate, achy, burning, non-triggered, dull pain. The pain may extend beyond the trigeminal distribution and may be on both sides of the face (bilateral). Patients may be depressed, and are more likely to be women. These patients are said to have “**atypical facial pain**” or neuropathic facial pain that is not otherwise specified. These patients should not be treated with TN procedures. They may benefit from Neurontin®, Lyrica®, or Elavil. If they fail conservative therapy, these patients can be considered for a neurosurgical neurostimulation trial procedure.

Finally, there are some patients in whom symptoms make them almost “borderline cases” between atypical trigeminal neuralgia and atypical facial pain. In these patients, there can be real uncertainty about the diagnosis. These patients can be considered for TN procedures with an understanding that results will not be as good as for other TN patients because the diagnosis is in question.

[There is another classification system recently proposed for trigeminal neuralgia that I do not agree with, but I present here for the sake of completeness. Under this system, all patients with spontaneous facial pain are said to have trigeminal neuralgia. Patients with pain that is mostly episodic are said to have trigeminal neuralgia type 1, or TN 1, and those patients with pain that is mostly constant are said to have trigeminal neuralgia type 2, or TN 2. Patients with facial pain and psychiatric problems, specifically “somatoform disorder,” are said to have “atypical facial pain.” The major clinical implication of this grading system, is that many people who clearly do not have trigeminal neuralgia and would normally be classified as “atypical facial pain” are being classified as “trigeminal neuralgia” under this system, particularly TN 2. Not surprisingly, when TN 2 patients have received standard TN operations, they have not done nearly as well as TN patients normally do, and this is likely because many of these patients simply do not have TN.]



Trigeminal nerve.

Causes of TN

TN is usually caused by a small blood vessel contacting or compressing the trigeminal nerve root. The usual offending vessel in TN is the superior cerebellar artery (SCA). Less often it is a trigeminal vein. Rarely it is a small unnamed arteriole or venule, or a large ectatic basilar artery. The second most common cause of TN is multiple sclerosis (MS), in which case the demyelinating process is thought to be the cause of the TN. In rare cases, TN is caused by a mass, like a benign tumor, that is against the intracranial trigeminal nerve.

TN in patients with Multiple Sclerosis

MS patients with TN have some differences when compared with other TN patients. In MS patients, the TN pain is more likely to occur at an earlier age, is more likely to have some atypical features, is more likely to involve both sides of the face though not usually at the same time, and tends to be a bit more difficult to treat.

Evaluation and Work up of TN patients

The standard workup of TN patients includes a good history, a physical exam, a dental evaluation, specific inquiries about prior facial rash or trauma, and then an MRI of the brain. Gadolinium at the time of the MRI may be useful to better evaluate for vascular compression or to see a tumor. Other things that may be seen on the MRI that may be of interest include the presence of T2 signal changes that might suggest MS, compression of the trigeminal nerve by a large vessel, such as a large ectatic basilar artery, a tumor or mass against the trigeminal nerve, a petrous endostosis, (bony overhang over the nerve), or a short cisternal segment of the trigeminal nerve. All these features could alter the decision making process. A special dedicated fine cut MRI with T2-like weighting (“FIESTA” sequence) through the trigeminal nerve area may be useful for actually seeing the vascular contact/compression against the trigeminal nerve root. It should be noted, however, that some degree of vascular contact with the trigeminal nerve is common, and that this finding is considered meaningful only in the setting of a history consistent with trigeminal neuralgia.

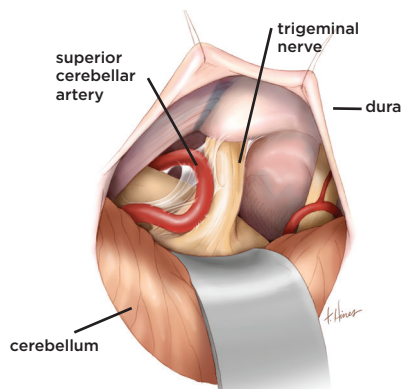
Medical Treatment for TN

The first line of treatment for TN is with medications. “Standard” pain medications are usually not effective for TN. TN is usually treated with “anticonvulsants” or anti-seizure medications. The medicine that is tried first is either Tegretol (carbamazepine) or Trileptal (oxcarbazepine). Tegretol is usually given three times a day, and trileptal usually twice a day. Trileptal tends to have fewer overall side effects, but is a little more likely to cause low serum sodium (hyponatremia). A second line of medical therapy involves the similar drugs Neurontin® (gabapentin) and Lyrica® (pregabalin). These medicines are usually given three times a day. All of these medicines may

cause general side effects like fatigue, dizziness, memory problems, and unsteadiness. As patients get older, they may have more trouble tolerating these medicines and the medicines may not be as effective. If a patient is not having good pain control with the medicines or having bothersome side effects from the medicines, a procedure should be considered. Other anticonvulsants may also be considered, but because there are several good procedures available, a procedure should usually be considered if a patient is still having problems despite a good trial with one or two of the above medicines. Because anticonvulsants pose some risk to the developing fetus, a young woman who is doing well with anticonvulsant medicines but wanted to get pregnant, would also be a candidate for a procedure.

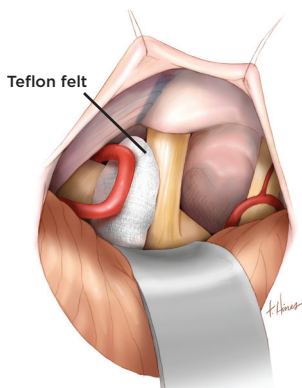
Procedures for TN

There are two types of “procedures” for TN. Microvascular Decompression (MVD) and Denervating (nerve-injuring) procedures. Denervating procedures include percutaneous trigeminal rhizotomy (either radiofrequency, glycerol, or balloon technique) or stereotactic radiosurgery (Gamma Knife or LINAC based). Any one particular procedure may be preferable for any given patient. None of the procedures are guaranteed to work, and for all of the procedures there is a recurrence rate even with successful treatment.



Blood vessel contacting trigeminal nerve.

Printed with permission from Mayfield Clinic



Teflon felt placed between blood vessel and trigeminal nerve.

Printed with permission from Mayfield Clinic

The Microvascular Decompression (MVD) for TN

The MVD is an operation to move the contacting blood vessel off the trigeminal nerve. Usually a microscopic piece of permanent material (usually Teflon felt) is placed between the nerve and blood vessel. This procedure is performed under general anesthesia. A 2 inch incision is made behind the ear, a small amount of skull bone is removed (about the size of a quarter), and under the microscope, the vessel is decompressed from the nerve. Patients usually stay in the hospital about two days. The operation usually works right away, usually medicines are no longer needed, and this procedure has the best chance of being curative. MVD is usually not appropriate for MS patients, in whom the presumptive cause of TN is not vascular compression. MVD carries a low risk of major complication in experienced hands, under 1%. These risks can include bleeding or infection, face numbness, face weakness, double vision, decreased hearing, weakness, numbness, heart problems, lung problems, or other uncertainties.

While the complication rate is very low, the MVD is still more invasive than the denervating procedures. MVD is usually considered the procedure of choice in younger, healthier patients without MS. Also, because MVD carries a small risk of decreased hearing (under 2%), it would be relatively contraindicated in a patient with very poor or no hearing in the opposite ear. Two other rare considerations that make the MVD a bit more technically challenging are if the offending vessel is the basilar artery, or if there is a large bony overhang over the nerve that needs to be drilled out at surgery. Because during MVD the nerve is not intentionally injured, MVD has the least chance of new numbness or dysesthesias (abnormal sensations) of the face. If an MVD is attempted and no vascular compression is identified, usually a small injury will be performed to the nerve, essentially an open denervation (microsurgical rhizotomy).

Denervating (nerve-blocking) procedures for TN

It has also been found that injuring the trigeminal nerve can also provide symptom relief. The original types of injuries performed on the trigeminal nerve were to peripheral branches of the nerve in the face, or “peripheral trigeminal neurectomies.” While these procedures could be effective, they were limited because

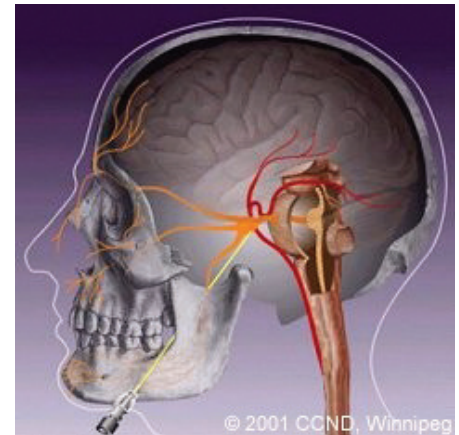
they caused dense numbness, had earlier recurrences, and were really limited to cases where pain was in a focused, superficial region of the face. It was subsequently found that injuring the nerve more proximally, closer to the exit from the brainstem, produced better, longer lasting pain relief, with less or no facial numbness. These procedures can be performed either “directly” with a needle placed into the proximal nerve (percutaneous trigeminal rhizotomy), or “indirectly” with super-focused radiation techniques. These are the denervating procedures that are currently offered for TN. These procedures are performed as an outpatient. They are much less invasive than the MVD, but have the downsides that they are more likely to have recurrences (because the nerve can regrow) and are more likely to cause some new numbness or dysesthesias (abnormal feelings) in the face (because the nerve is intentionally injured and it is not possible to control 100% exactly how much injury the nerve will get)..

Percutaneous Trigeminal Rhizotomy (PTR) for TN

PTR is an outpatient, minimally invasive technique for treating TN. The procedure is performed in the operating room and takes less than 30 minutes. The patient is given intravenous sedation, local anesthetic is applied to the cheek on the affected side, and a needle is inserted into the cheek about one inch from the corner of the mouth. Under fluoroscopic (live x-ray) guidance, the needle is directed through the hole where the nerve comes out of the skull base, the “foramen ovale.” The needle is advanced a bit past this hole in the skull base, towards the area of the nerve ganglion. The nerve is subsequently injured either with heat (radiofrequency technique), alcohol (the glycerol technique), or mechanical compression (the balloon technique). The needle is then withdrawn.

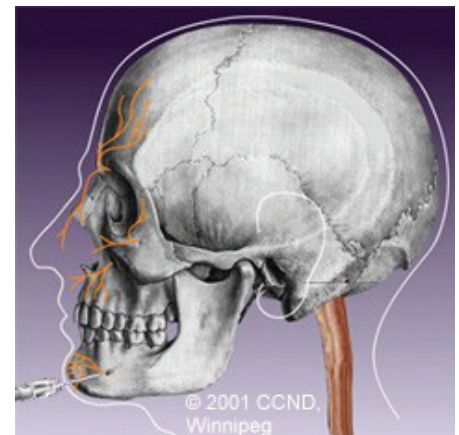
For the **radiofrequency technique**, the patient is woken up once the needle is in place, and then the nerve is stimulated. This produces a brief sensation in the face. The purpose of this is to position the needle in the division of the nerve that is causing the pain (for example, the jaw area, or the cheek area). Once the position is confirmed, the needle is heated for a minute (usually to 70 degrees centigrade), and a small injury is thus created in the nerve. The radiofrequency technique is the only injuring technique that can be “selective,” that is, it can try to injure just the second division or just the third division of the nerve. The radiofrequency technique is best done if reliable stimulation can be obtained in the operating room in the area of the pain. Radiofrequency should be used with caution if there is a major V1 component to the pain, as radiofrequency is a little more likely to result in overnumbing of the cornea in these cases.

The **glycerol technique** involves injecting glycerol, a type of alcohol, into the cerebro-spinal fluid that bathes the trigeminal nucleus or “ganglion.” It is therefore preferable if cerebro-spinal fluid is seen coming from the needle. Before injection of the glycerol, the patient is seated upright. Only a tiny amount of glycerol is injected, about 0.25 to 0.3 cc’s. Once injected, the patient is brought to the recovery room and kept seated upright for 2 hours so the glycerol does not wash away from the nerve.



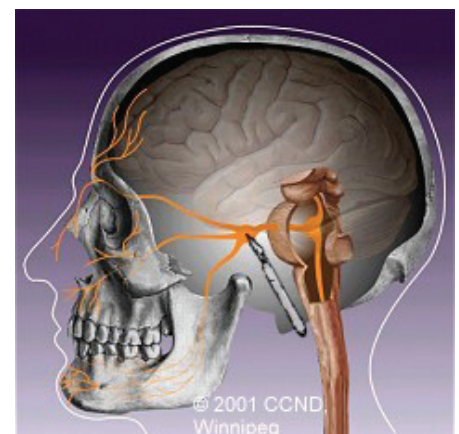
Percutaneous Trigeminal Rhizotomy

© 2001 Centre for Cranial Nerve Disorders, Winnipeg, University of Manitoba, Health Sciences Centre.



Peripheral Trigeminal Neurectomy

© 2001 Centre for Cranial Nerve Disorders, Winnipeg, University of Manitoba, Health Sciences Centre.



Micro-Surgical Trigeminal Rhizotomy

© 2001 Centre for Cranial Nerve Disorders, Winnipeg, University of Manitoba, Health Sciences Centre.

The glycerol sometimes irritates the nerve briefly after injection, though this suggests a successfully placed injection.

For the **balloon technique**, a small balloon is inflated (to about 0.6cc-1 cc) against the trigeminal nerve for about a minute. This squeezes and injures the nerve a bit. This technique has a low chance of causing a transient diplopia (double vision) because of compression against the nearby nerves in the cavernous sinus. It is also a bit more likely to affect the motor component of the trigeminal nerve which primarily involves some of the “chewing” muscles. This can lead to difficulty opening the mouth all the way, but this is usually not that bothersome, and again, is usually temporary.

All of the PTR techniques carry a slight risk of bleeding or infection in the head. This is extremely rare though. The PTR techniques usually provide immediate pain relief, though sometimes relief can take 1-2 weeks. When successful, patients usually can stop all trigeminal medications. When I perform the PTR procedure, I am set up to use all three techniques as sometimes there are issues that are appreciated only during the procedure that might favor one technique over the other.

My algorithm for PTR preference is as follows:

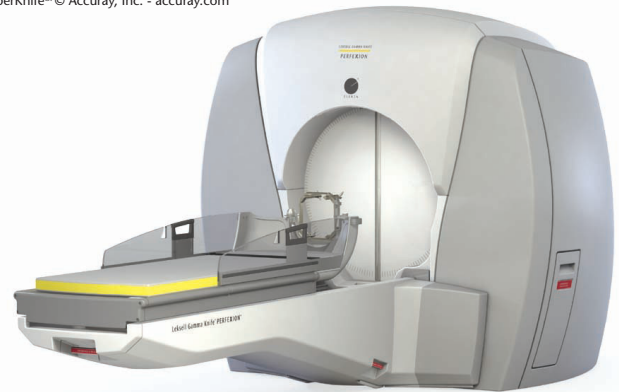V2, V3, or V2+3 pain	Any major V1 pain
1) Radiofrequency	1) Balloon
2) Glycerol	2) Glycerol
3) Balloon	3) Radiofrequency

Stereotactic Radiosurgery (SRS) treatment / Gamma Knife® for TN

Stereotactic radiosurgery (SRS) , or just “radiosurgery” involves super-focusing radiation beams on a target. In addition to TN, SRS is used to treat brain and spinal tumors (benign and malignant) and arteriovenous malformations (AVM’s). One of the original intended uses of SRS was trigeminal neuralgia. SRS is the least invasive procedure option for trigeminal neuralgia. It involves a single session where multiple invisible radiation beams are focused on the trigeminal



CyberKnife® © Accuray, Inc. - accuray.com



Gamma Knife® Perfection™. © Elekta AB. - elekta.com

nerve to injure it slightly, again with the intent of alleviating the facial pain. SRS for TN is usually performed with a machine called the “Gamma Knife®.” This device uses focused radiation from gamma rays, and planning is performed off an MRI done on the day of treatment. If the patient has a pacemaker and cannot get an MRI, planning is performed off a CT scan done after a cisternogram (injection of a radio-opaque material through a lumbar puncture), so the trigeminal nerve can be visualized. The head is rigidly immobilized during treatment with a headframe which is applied with local anesthesia and moderate sedation. Gamma Knife® has the longest history and the most data for TN radiosurgery treatments. More recently, certain linear accelerators have developed platforms to treat TN. These devices include the CyberKnife® and Novalis™. These devices use focused radiation from x-rays, and planning is usually off a CT scan with an image fusion to an MRI. Often these treatments are done in conjunction with a lumbar puncture, again, to better visualize the trigeminal nerve on the CT scan. With Linac based SRS, the head is immobilized either in a headframe or with a very conformal mask.

SRS for TN is the least invasive procedure option. There is essentially no risk of bleeding or infection in the brain that can rarely be seen with PTR.

Unlike PTR, SRS can take several weeks to work, and sometimes patients will still have to take some medications, albeit usually with lower doses. Also, unlike PTR where facial numbness usually presents fairly quickly, with SRS, patients who develop numbness or dysesthesias will do so months or years later.

Further considerations for Denervating Techniques (PTR and SRS) for TN

Like MVD, the nerve-injuring procedures (PTR and SRS) are not guaranteed to work. They may also work and wear off with time. The PTR and SRS have higher recurrence rates than MVD because the nerve can regrow over time.

Patients who have PTR or SRS do not usually develop numbness or dysesthesias. When patients do develop numbness, it usually suggests there has been a good nerve injury, and there is usually good pain relief of the TN. The numbness often will get better as the nerve regrows, but this can take months or years. The numbness is usually better tolerated by older patients or patients with MS. If a patient develops eye or cornea numbness, they are usually advised to use regular eye drops and follow up periodically with an ophthalmologist.

As a general rule with the nerve-injuring procedures, the greater the injury, the greater the likelihood that the TN pain will resolve, and the greater the likelihood that the pain relief will be longer lasting. However, with greater injuries, there is also a greater likelihood of facial numbness or dysesthesias. It is also true that small injuries to the nerve will often provide good pain relief. For this reason, most surgeons tend to give smaller nerve injuries with the thought that the procedure can be easily repeated if there is not enough injury, whereas it is harder to deal with too much nerve injury. Dysesthesias from over-injury to the nerve can be treated with Neurontin®, Lyrica®, or Elavil if bothersome. The extreme form of facial numbness and dysesthesias is referred to as “anesthesia dolorosa.”

Repeat denervating procedures are more likely to produce some facial numbness or dysesthesias, particularly if the patient already has some degree of numbness or dysesthesias to start with. For this reason, in a patient who has had

a prior denervating procedure and has a good deal of numbness or dysesthesias, an MVD would be reasonable to consider if the patient was otherwise a candidate for MVD.

Some patients with TN who require treatment are on blood thinners or “anticoagulants”, such as Coumadin (warfarin), plavix or aspirin. Usually this is not an issue as patients can often stop their blood thinners for brief periods of time. MVD, PTR, and lumbar punctures can only be done OFF all anticoagulants. Gamma Knife can be done on anticoagulants if needed.

PTR is considered preferable to SRS if the person needs immediate pain relief or has a high priority to be completely off medicines. Gamma Knife is preferable if the patient cannot safely discontinue blood thinners. Otherwise either PTR or SRS can be considered.

Recurrence of TN pain after treatment and need for multiple treatments

Recurrences after any treatment are dependent on time. Therefore, the younger the patient, the more likely they will need another procedure in their lifetimes. Also, recurrences are more likely with the denervating procedures. Performing one procedure does not preclude another procedure. Repeat MVD procedures have significant increase in complication rate compared to original MVD's because of scarring and disruptions of the normal anatomy. Also, repeat MVD's are much more likely to cause new numbness and dysesthesias because of dissection of a scarred-in trigeminal nerve. I believe, like many neurosurgeons, that a repeat MVD is often not much different than an open rhizotomy. As such, I am very reluctant to perform repeat MVD's, except in very unusual circumstances. I prefer not to perform a repeat Gamma Knife procedure for at least a year after the first procedure, and preferably two or three years. This is because it can take a while to see the full effects of the original radiation treatment. While there is not much data on a third Gamma Knife procedure, I will offer this to elderly patients who are several years out from their second Gamma Knife procedure. PTR can be performed multiple times without problems. Finally, if a person has bilateral trigeminal neuralgia, it is reasonable to perform a treatment for both sides, but I will not perform both treatments at the same time.

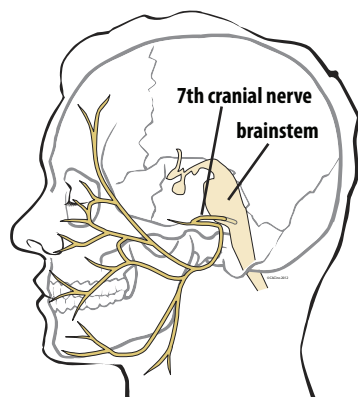


Figure 1. The facial nerve (7th cranial nerve) originates in the brainstem and exits the skull beneath the ear where it has five main branches that control the muscles of facial expression.

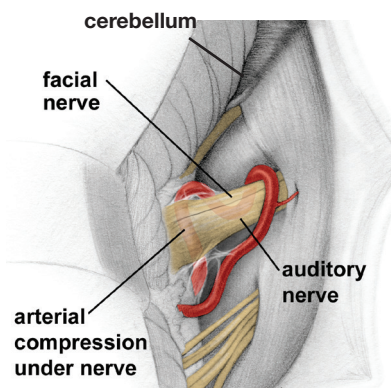


Figure 2. Hemifacial spasm is most often caused by an artery compressing the facial nerve.

Printed with permission from Mayfield Clinic

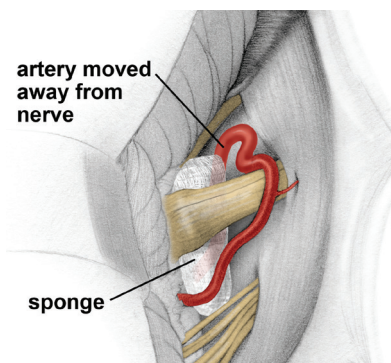


Figure 3. During surgery, a sponge is inserted between the artery and the nerve to relieve the pressure and stop the facial muscle spasms.

Printed with permission from Mayfield Clinic

Hemifacial Spasm (HFS)

General Considerations and Presenting Symptoms

The annual incidence of HFS is about 1 in 20,000 people. The average age of presentation is in the 40's. There is a modest male preponderance. The left side is somewhat more likely to be affected than the right side. People with HFS experience intermittent twitches or spasms of one side of the face. The spasms can involve any part of the face. HFS usually affects just one side of the face, though rarely a patient will have HFS on both sides of the face. HFS occurs spontaneously. HFS is usually sporadic, but in rare cases there will be other family members with HFS. HFS involves brief, sudden episodes of facial twitching that can sometimes be brought on by voluntary facial movements. Spontaneous remissions can occur. The spasms may occur in varying degrees of severity. Sometimes patients will exhibit mild facial weakness when the face is not twitching. In rare cases, patients with HFS will also have TN.

Causes of HFS

HFS is usually caused by a small blood vessel contacting or compressing the nerve root of the facial (7th) cranial nerve. The most common offending vessel is the Posterior Inferior Cerebellar Artery (PICA). Less commonly the vessel is the Anterior Inferior Cerebellar Artery (AICA), the Vertebral Artery, or a nearby vein. In rare cases, HFS can be caused by MS or a mass against the facial nerve root. HFS can also occur after injury or disease of the facial nerve, such as an episode of Bell's palsy.

Evaluation and Work up of HFS patients

The standard workup of HFS patients includes a history, physical exam and then an MRI of the brain. MRI with gadolinium may be useful as is a fine cut "FIESTA" sequence that may better show the contact of the blood vessel with the facial nerve.

Medical Treatment for HFS

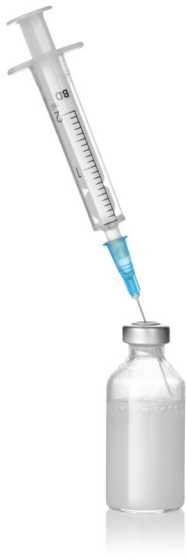Like with TN, first line medicines to consider for HFS are Tegretol and Trileptal. Second line medicines are Neurontin® and Lyrica®. Medicines tend to not be quite as effective for HFS as for TN.

Procedures for HFS

Like with TN, there are two types of procedures for HFS: Microvascular Decompression (MVD) and Denervation (done with Botox injections in the affected areas of the face).

The Microvascular Decompression (MVD) for HFS

The MVD for HFS is fundamentally very similar to the MVD for TN, except that the blood vessel is being moved away from the nerve root of the 7th (facial) nerve, rather than the nearby 5th (trigeminal) cranial nerve. Because the dissection involves



primarily the 7th and adjacent 8th cranial nerves (the nerve for hearing), there is a slightly increased chance of some facial weakness or decreased hearing in the ear on that side, compared with MVD for TN. Nonetheless, these risks are very low. MVD would not be appropriate for a patient with MS. MVD is appropriate for young, healthy patients who are very bothered by their symptoms and not satisfied with the other treatment options (medicines and botox injections).

Botox Injections for HFS

Multiple superficial injections of Botulinum toxin (Botox) in the facial muscles can also be administered as a treatment for HFS. This is a low risk, outpatient procedure. The major downsides to this treatment is first that the treatment needs to be repeated every few months (because the botox wears off), and second, that there is some chance with each injection of over-injury, and facial weakness. If this does occur, it does wear off over the subsequent weeks.

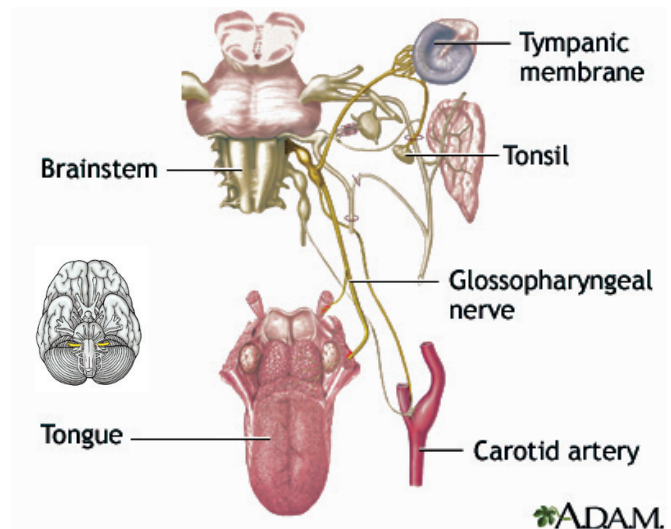
Glossopharyngeal Neuralgia (GPN)

General Considerations and Presenting Symptoms

GPN is the least common of the cranial nerve compression syndromes. The annual incidence of GPN is about 1 in 125,000 people. GPN is a pain disorder very similar in nature to TN, except that the pain is experienced in the distribution of the ninth cranial nerve (glossopharyngeal) instead of the fifth cranial nerve (trigeminal). In GPN, pain can be experienced anywhere in the sensory distribution of the ninth cranial nerve, including the ear, throat, tonsils, and tongue. GPN usually involves just one side of the face. GPN is rarely bilateral, but usually not symptomatic on both sides at the same time. In rare cases, patients with GPN can also have TN.

GPN occurs spontaneously. Classic GPN pain is intermittent, sharp, severe, electric shock pain. It is excruciating. The sharp pains can be described as “electric shock,” “stabbing,” or “intense.”

GPN pain occurs suddenly, is brief, and can be triggered by light stimulation in the distribution of the ninth nerve, such as eating, swallowing, speaking, or coughing. GPN may demonstrate spontaneous remission. Physical exam is normal. GPN is usually sporadic, but rare familial cases have been described. In a minority of cases,



GPN patients may also have potentially life threatening episodes of arrhythmias, bradycardia, hypotension, and syncope. These phenomena implicate some involvement of the adjacent vagus nerve, the 10th cranial nerve.

Further Classification of GPN

As with TN, some patients with GPN will sometimes have some non-classic or “atypical” features. GPN may then be referred to as “atypical

glossopharyngeal neuralgia.” These atypical features can include some dull, or achy, or burning components to the pain. There may also be some baseline of constant pain. Sometimes the pains are not clearly triggered. Sometimes there is no good response to medication. Nonetheless, if the patient has a major feature of sharp, sudden, severe, brief pains in the glossopharyngeal distribution, the problem is still felt to be GPN, and should be treated according to the usual GPN algorithm.

Sometimes the pain of GPN may be mediated not just by the ninth nerve, but partly by the tenth cranial nerve, the “vagus” nerve. This was determined, because in the past, one of the operations to treat GPN was to cut the ninth nerve, and it was found that some patients would still have pain, but that pain was more consistently eliminated if both the ninth nerve and the uppermost fibers of the tenth nerve were also cut. Also, implicating some vagus nerve involvement in this disease are the syncopal episodes some of these patients experience, associated with bradycardia, hypotension, and cardiac arrhythmias. Finally, at surgery, there often will appear to be vascular compression of not just the ninth cranial nerve, but also the adjacent 10th nerve. Some people therefore believe that GPN is more appropriately called “**vagoglossopharyngeal neuralgia.**”

Causes of GPN

The usual cause of GPN is compression of the ninth and possibly the tenth nerves by a blood vessel, usually the Posterior Inferior Cerebellar Artery (PICA) or the vertebral artery, but sometimes by a small arteriole or venule. Rarely, GPN can be caused by either MS or by a tumor compressing the ninth nerve.

Evaluation and Workup of GPN patients

The workup of GPN patients involves a history, physical and and MRI. Again, a fine cut “Fiesta” sequence may best demonstrate the compression of the blood vessel against the ninth nerve.

Medical Treatment for GPN

The first line treatment of GPN is with anticonvulsant medicines, usually Tegretol or Trileptal. These are usually quite effective, if tolerated, at least at first. Second line medicines are Neurontin® or Lyrica®. Standard pain medicines are usually not effective.

Procedures for GPN

If a patient is having pain despite medicines or having significant side effects from the medicines, a procedure should be considered. Procedures include MVD or nerve injuring procedures.

The Microvascular Decompression (MVD) for GPN

The MVD for GPN is similar to the MVD for TN or HFS, except that it is the ninth and tenth nerves that are being decompressed. Because the MVD for GPN involves manipulation of the tenth nerve, hoarseness and swallowing difficulty can occur, though this is rare and usually temporary. If no vascular compression is noted, the ninth nerve and upper two fibers of the tenth nerve are cut, which should not cause any significant clinical problem. MVD is appropriate for younger, healthier patients with symptoms despite medicines or significant side effects from the medicines.

Denervating (nerve-blocking) procedures for GPN

In the past, a percutaneous rhizotomy was offered to patients with GPN, much like for TN, but because of difficulty controlling the injury to the tenth nerve with this technique, this procedure is not used much anymore. Denervation with Stereotactic Radiosurgery does seem to be safe, however, and can be considered for patients who are elderly, have medical problems, are otherwise reluctant to have the MVD, or in patients with MS.

Stereotactic Radiosurgery (SRS) treatment / Gamma Knife for GPN

SRS for GPN is performed in a manner very similar to SRS for TN, except that for GPN, the ninth nerve is targeted.

CHART SUMMARY

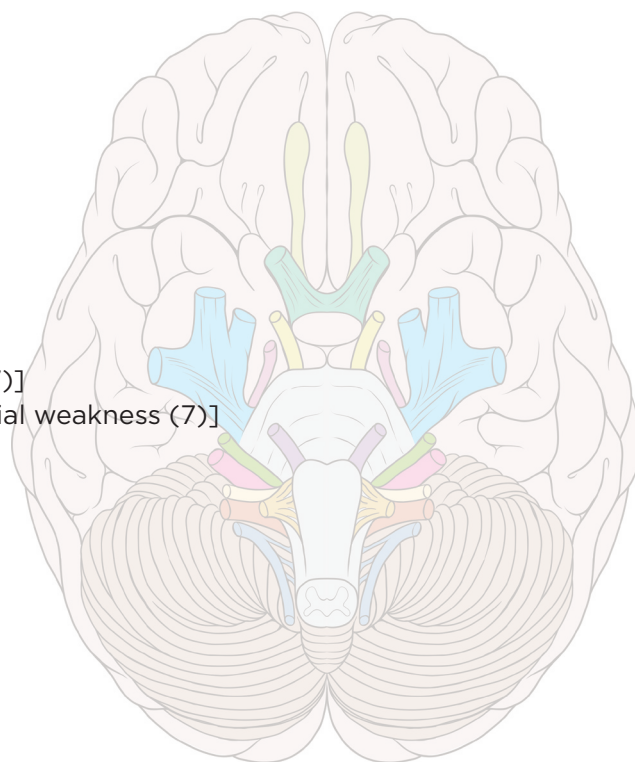
Cranial Nerve Root Vascular Compression / Hyperactivity Syndromes (Nerves 5,7 and 9)

Spontaneous
 Sporadic (no family history)
 Sharp (5,9)
 Severe (5,9)
 Sudden
 Short-lived
 Set off (triggered)
 Sign free (normal exam) (5,9)
 Sensitive to anticonvulsants (particularly 5,9)
 Spontaneous remissions

Involve hyperactivity of the nerve [pain (5,9) or twitching (7)]
 Can have underactivity of the nerve [numbness (5,9), or facial weakness (7)]
 Can be bilateral (both sides of face)
 Can be familial

Usually caused by vascular compression
 Can be caused by MS
 Can be caused by tumor or other mass

Can respond to anticonvulsants
 Can respond to denervation
 Can respond to MVD



Summary of Treatment Options for TN, HFS, and GPN (medicine/denervation/mvd)

Trigeminal Neuralgia

Anticonvulsants
 Percutaneous Rhizotomy or Radiosurgery
 MVD

Hemifacial Spasm

Anticonvulsants
 Botox
 MVD

Glossopharyngeal Neuralgia

Anticonvulsants
 Radiosurgery
 MVD

Key Considerations in Algorithm for managing cranial nerve compression syndromes (TN, HFS, GPN):

Is this Trigeminal Neuralgia, Hemifacial Spasm, or Glossopharyngeal Neuralgia?

Has Patient Failed Medication?

MVD vs. Denervating Procedure?



NSPC

Brain & Spine Surgery

One Hollow Lane • Suite 212
Lake Success, NY 11042

Join us on Facebook, Twitter, LinkedIn, YouTube! Visit www.nspc.com and click through.



MICHAEL H. BRISMAN, M.D., F.A.C.S.

Neurosurgeon

After receiving his undergraduate degree with high honors in Biology from Harvard University, Dr. Brisman obtained his medical degree from Columbia College of Physicians and Surgeons. He then completed a General Surgery internship and Neurological Surgery residency at the Mount Sinai Medical Center in New York City where he was appointed Chief Resident in his final year of residency.

Board certified by the American Board of Neurological Surgeons and a Fellow of the American College of Surgeons, Dr. Brisman specializes in the treatment of Trigeminal Neuralgia and Brain Tumors. He serves as the Co-Medical Director of the Long Island Gamma Knife Center at Mount Sinai South Nassau Hospital in Oceanside and has served as the Chief of Neurosurgery at NYU-Winthrop Hospital in Mineola. In addition, Dr. Brisman has also served as the President of both the Nassau County Medical Society and the New York State Neurosurgical Society.

nspc.com

Dr. Brisman Treats:

- Trigeminal Neuralgia
- Gliomas
- Brain Tumors
- Brain AVMS
- Pituitary Tumors
- Hemifacial Spasm
- Meningiomas
- Glossopharyngeal Neuralgia
- Acoustic Neuromas
- Skull Tumors
- Brain Metastases

Dr. Brisman is proficient in the use of minimally invasive neurosurgical procedures including:

- Stereotactic Radiosurgery
- Gamma Knife®
- CyberKnife®
- Novalis Tx®
- Microvascular Decompression
- Neuroendoscopy
- Transsphenoidal Surgery
- Stereotactic-guided Craniotomy
- Percutaneous Trigeminal Rhizotomy